

TEN

Titanium ElasticNail

Surgical Technique

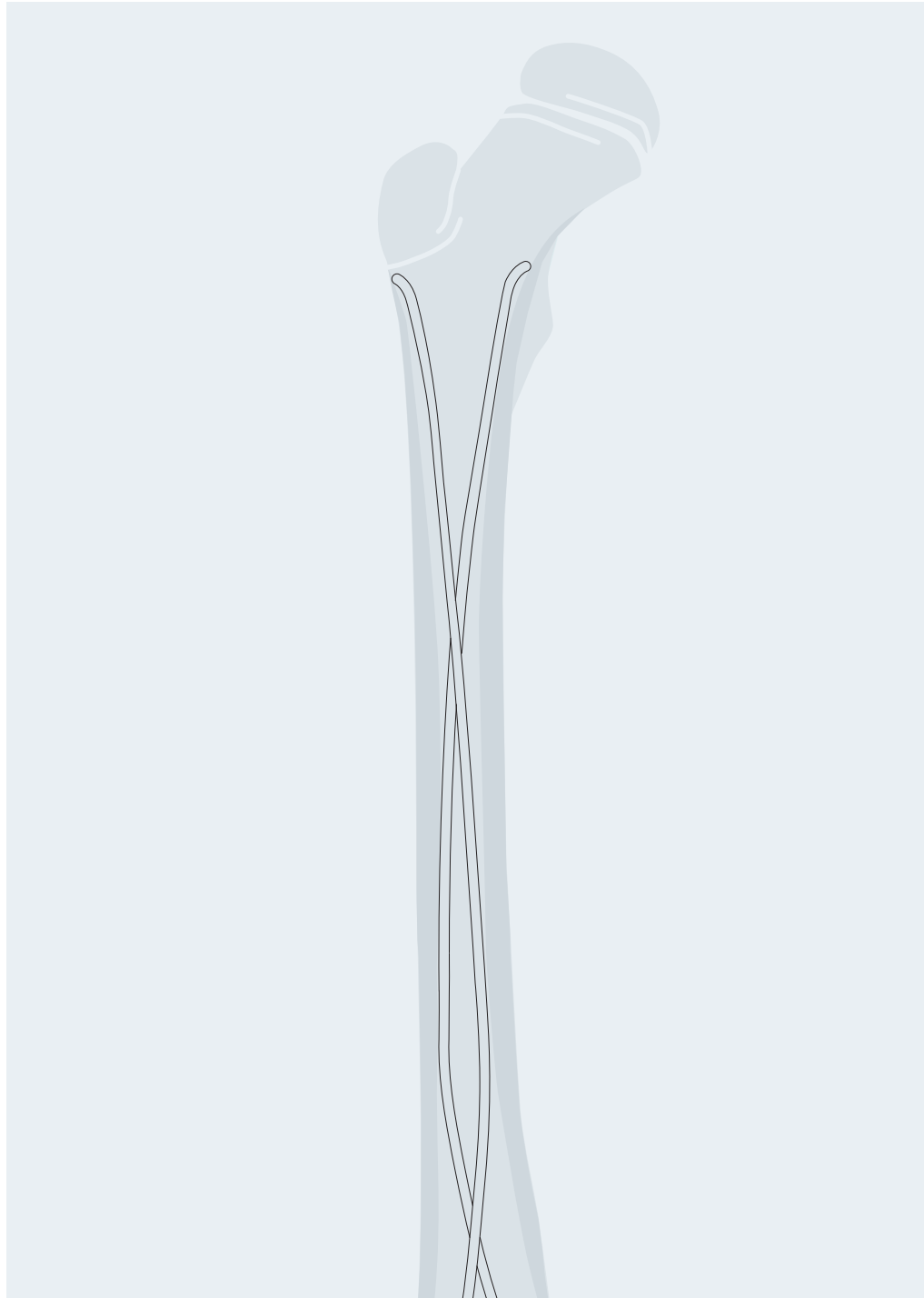

Table of contents

System description	2
Indications/Contraindications	3
Standard surgical technique	4
Assembly and handling instructions for the Cutter for TEN	11
Additional applications	12
Implant removal	21
Case studies	22
Bibliography	25

 Image intensifier control

Warning

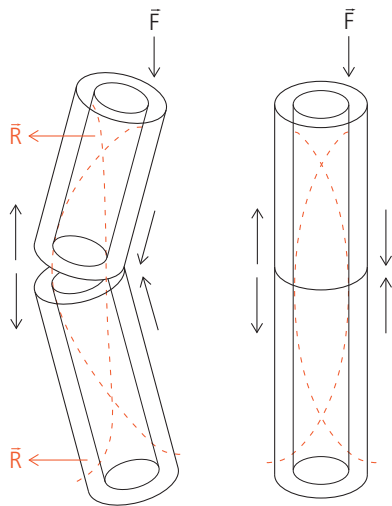
This description is not sufficient for immediate application of the instrumentation. Instruction by a surgeon experienced in handling this instrumentation is highly recommended.

System description

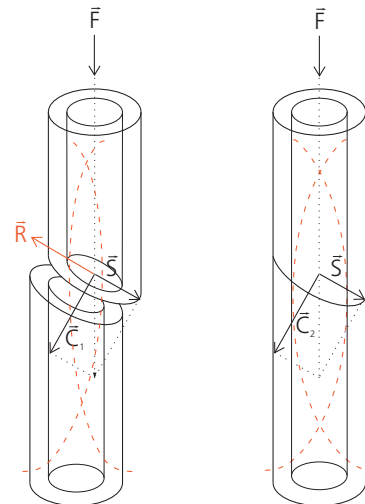
The aim of this biological, minimally invasive fracture treatment is to achieve a level of reduction and stabilisation that is appropriate to the age of the child.

The biomechanical principle of the elastically-stable intra-medullary nailing (ESIN) is based on the symmetrical bracing action of two elastic nails inserted into the metaphysis, each of which bears against the inner bone at three points. This produces the following four biomechanical properties: flexural stability, axial stability, translational stability and rotational stability. All four are essential for achieving optimal results (Ref.: Dietz et al. 1997).

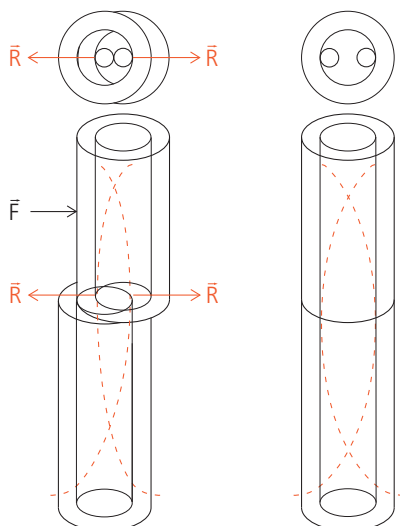
Flexural stability



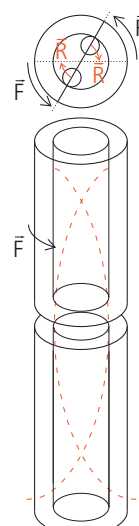
Axial stability



Translational stability



Rotational stability



F = force acting on the bone
 R = restoring force of the nail
 S = shear force
 C = compressive force

Indications/Contraindications

Elastically-stable intramedullary nailing with the TEN Titanium ElasticNail is used primarily for the management of diaphyseal and metaphyseal fractures in children. Whether the TEN is indicated or not depends upon the age of the patient and the type and site of the fracture.

All three factors must be considered together.

Age

The age limit depends on the biological development of the child. Experience has shown that the lower limit is 3–4 years and the upper limit 13–15 years.

Type of fracture

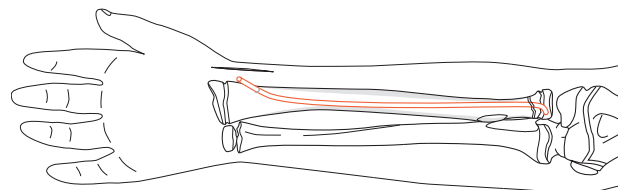
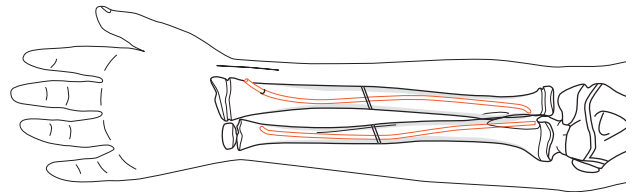
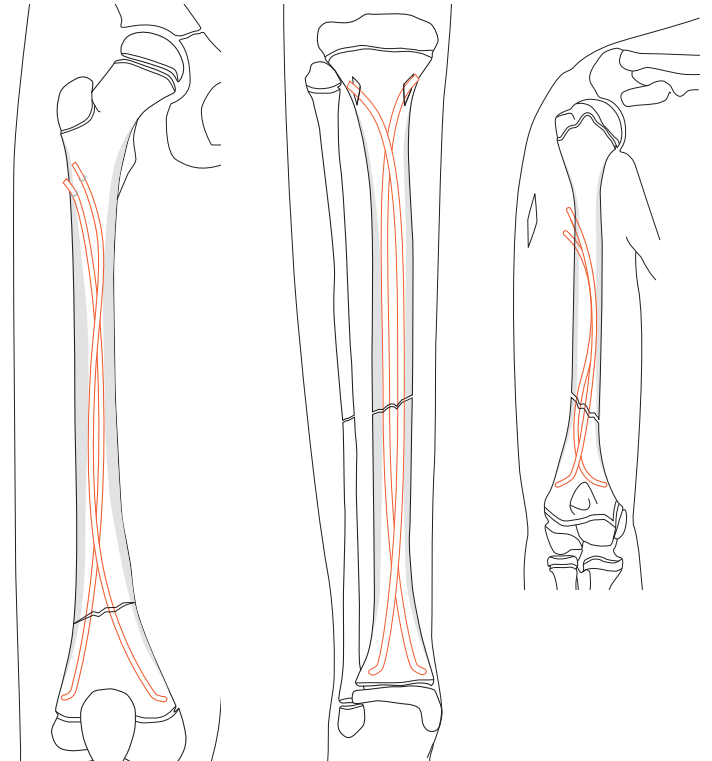
- transverse fractures
- short oblique or transverse fractures with broken-off wedges
- long oblique fractures with the possibility of cortical support
- spiral fractures
- multi-fragment and bifocal fractures
- pathological fractures with juvenile bone cysts

Fracture site

- femur: diaphyseal
- distal femur: metaphyseal
- femur: subtrochanteric
- lower leg: diaphyseal
- lower leg: distal metaphyseal
- humerus: diaphyseal and subcapital
- humerus: supracondylar
- radius and ulna: shaft
- radius: neck

Other possible special indications:

- humerus and forearm in adults
- polytrauma in combination with craniocerebral trauma, even outside the age range specified above
- prophylactic stabilization with juvenile bone cysts
- osteogenesis imperfecta



Contraindications

- intraarticular fractures
- complex femoral fractures, particularly in connection with overweight (50–60 kg) and/or age (15–16 years)

Standard surgical technique

This surgical technique is explained using the example of a femoral shaft fracture and the ascending technique. Variants of this standard technique are described in "Additional applications" on page 12.

Careful preoperative planning, the correct choice of implant and a precise rotation check on the basis of the non-operated extremity are all vital for a good surgical result.


1

Position child

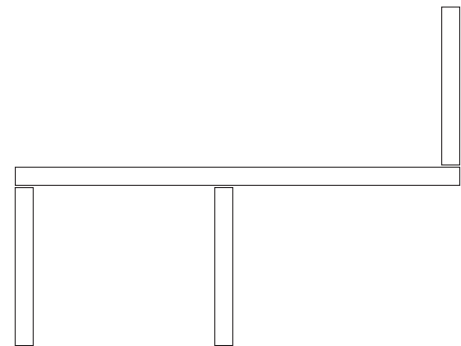
Place the child in a supine position on a radiolucent operating table. The extension table can be used for larger children. Secure small children to the operating table. The assistant extends the injured extremity. Free positioning allows better control of the nail position and rotation. Position the image intensifier so that AP and lateral X-rays can be recorded over the full length of the femur.

2

Reduce fracture

 If the extension table is used, reduce the fracture preoperatively, while closed, under image intensifier control. If the child is freely positioned, the fracture is reduced during the operation. For complex fractures, cover both legs with sterile sheets so that a rotation comparison can be performed during operation.

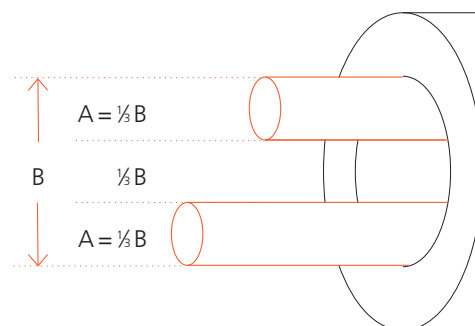
Fracture reduction can be facilitated by the use of the small F-tool (359.209). Position the F-tool at the level of the fracture so that the two identically aligned arms of the lever bring the fragments into the desired position.



3

Determine nail diameter

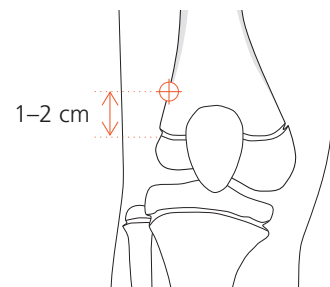
Measure the isthmus of the medullary cavity on the X-ray image. The diameter of the individual nail (A) should be 30–40% of the diameter of the medullary cavity (B). Choose nails with identical diameter to avoid varus or valgus mal-positioning.



4

Determine nail insertion points

For the ascending technique, the insertion points on the femur are 1–2 cm proximal to the distal epiphyseal plate. In children, this is about one fingerbreadth proximal to the upper pole of the patella.



- ⓘ If necessary, check the intended insertion points under the image intensifier.

5

Perform incisions

Make the opposing medial and lateral skin incisions at the planned insertion points and cut distally for 3–4 cm, depending on the size of the child. On the lateral side especially, the incision of the fascia should be of the same length.

Important: Ensure that the insertion points are outside the joint capsule and be careful to avoid the epiphyseal plates.

6

Open medullary cavity

Precisely matched opening of the medullary cavity on both sides is essential for optimal symmetrical bracing.

Divide the fascia lata over a sufficient length. Vertically insert the Awl (359.213) down to the bone and firmly make a centre mark. With rotating movements, lower the awl down to an angle of 45° in relation to the shaft axis and continue perforating the cortical bone at an upward angle. The opening should be slightly larger than the selected nail diameter.

- ⓘ Check the position and insertion depth of the awl with the image intensifier.

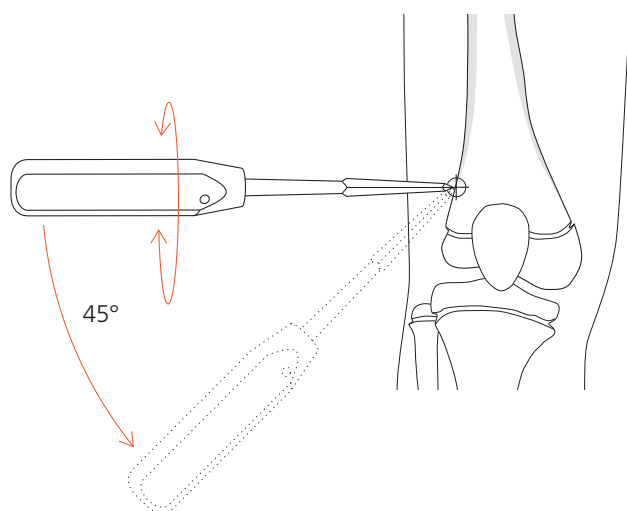
Repeat this procedure for access on the opposite side.

Alternative

If the cortical bone is very hard, open up the medullary cavity with the corresponding Drill Bit (315.280/290/480) and the Double Drill Guide 4.5/3.2 (312.460). Check the position and insertion depth of the drill bit with the image intensifier.



Note: Lower the drill by 45° only when the drill is running, otherwise the tip may break.

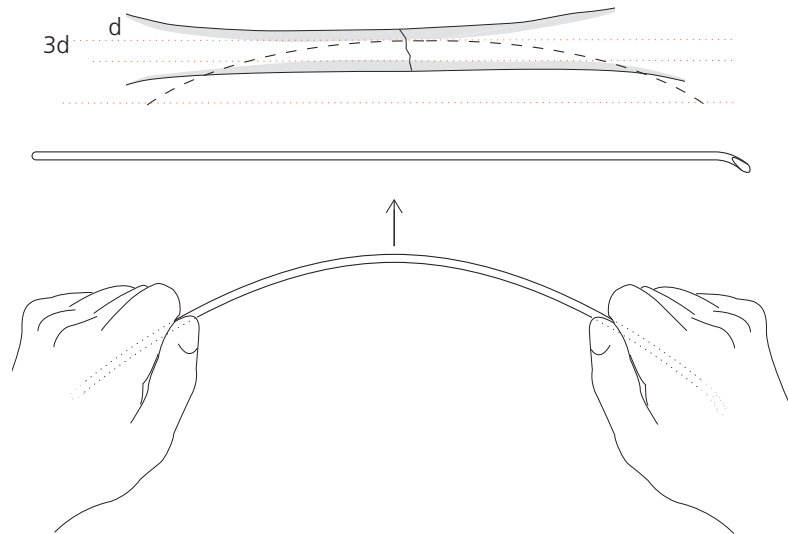


7

Pre-bend nails

We recommend pre-bending of the implanted part of the nails to three times the diameter of the medullary canal. The vertex of the arch should be located at the level of the fracture zone. The nail tip should form the continuation of the arch. Pre-bend both nails in exactly the same way.

Note: The pressure applied internally can be increased by pre-bending the nails to a smaller diameter, thus shifting the nail crossover points more towards the metaphyses. This can increase the stability in complex fractures.



8

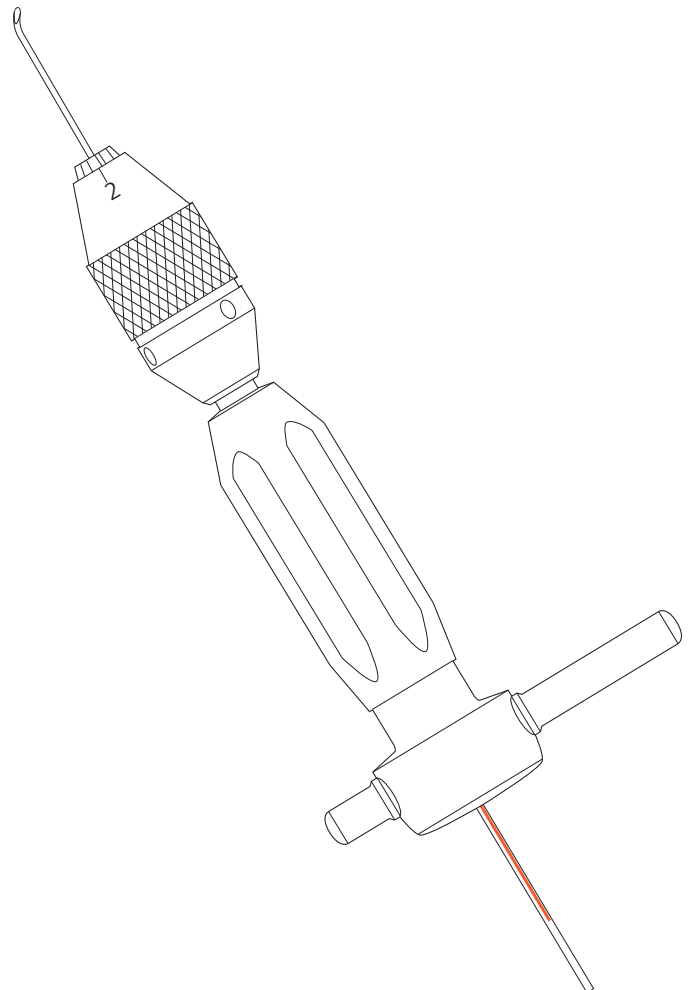
Load first nail in the inserter

Load the first nail in the inserter (359.219). Align the laser marking on the end of the nail with one of the guide markings on the inserter (laser markings at the tip, asymmetrical transverse bolts at the end). This permits direct visual control of the alignment and rotation of the nail tip in the bone without an image intensifier, thus preventing excessive crossover of the nails (corkscrew effect).

Tighten the nail in the inserter in the desired position using the Pin Wrench (321.170) or the Spanner Wrench (321.250).

Alternative

Use the long Inserter (359.201) or the Universal Drill Chuck with T-Handle (393.100). Do not, under any circumstances, strike the universal drill chuck with T-handle with a hammer.

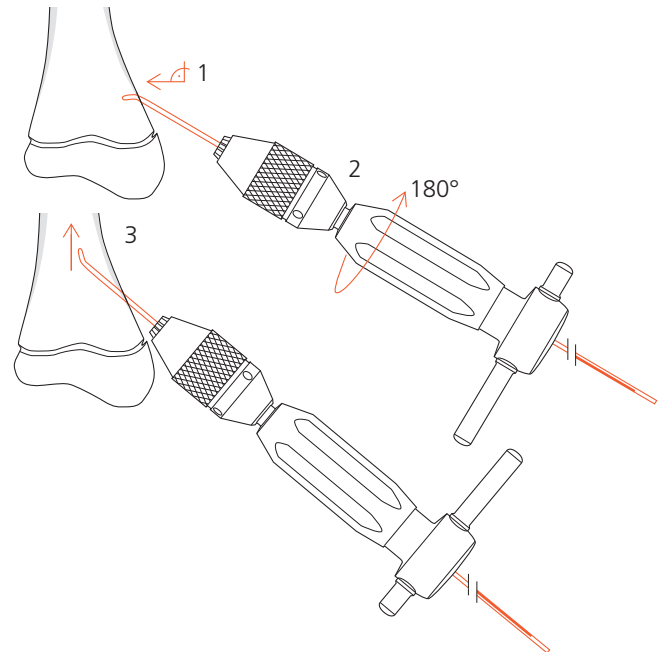


9

Insert first nail

Insert the nail into the medullary cavity with the nail tip at right angles to the bone shaft (1). Turn the inserter through 180° (2) and align the nail tip with the axis of the medullary cavity (3). If necessary, check the position of the nail tip with the image intensifier.

Note: The laser marking on the end of the nail shows the nail tip alignment. This facilitates nail insertion and helps reduce the X-ray exposure time.



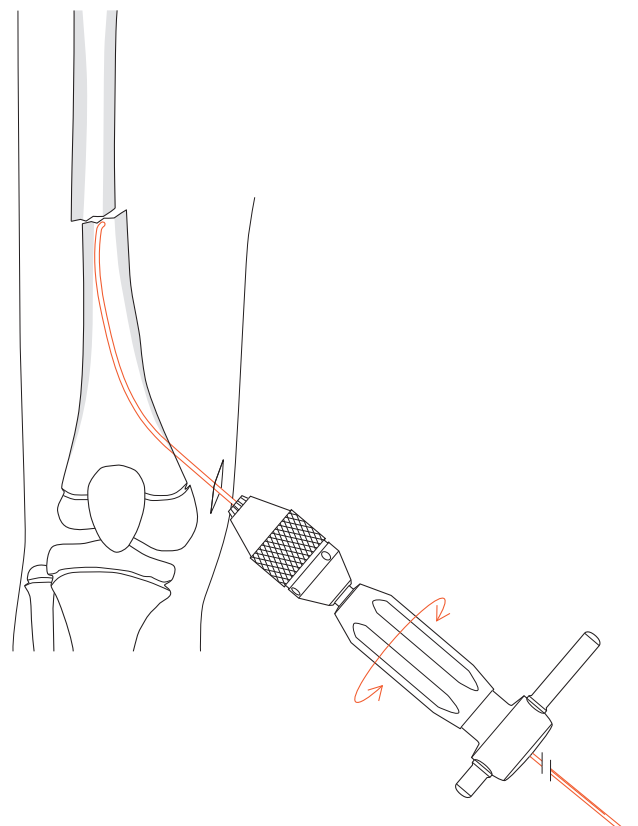
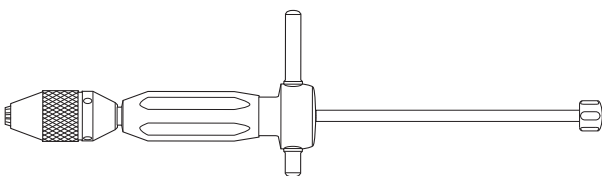
10

Advance first nail to the fracture zone

Advance the nail manually up to the fracture site, using rotating movements or gentle taps of the Combined Hammer (359.221) against the striking surface of the inserter. Do not strike the T-pieces.

Option

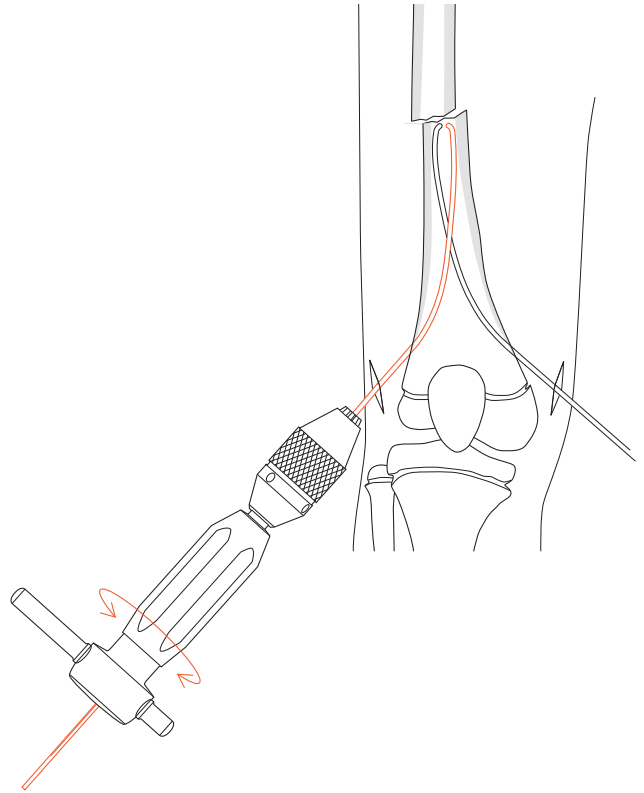
If more forceful hammer blows prove necessary, or if the nail needs to be moved back and forth in a targeted manner to achieve fracture reduction, screw the Hammer Guide (359.218) firmly into the inserter, if necessary with the aid of the pin wrench (321.170). Use the combined hammer or Slotted Hammer (357.026).



11

Insert second nail

Repeat steps 8 to 10 for the second nail at the opposing insertion point, thereby producing the first crossover of the nails.

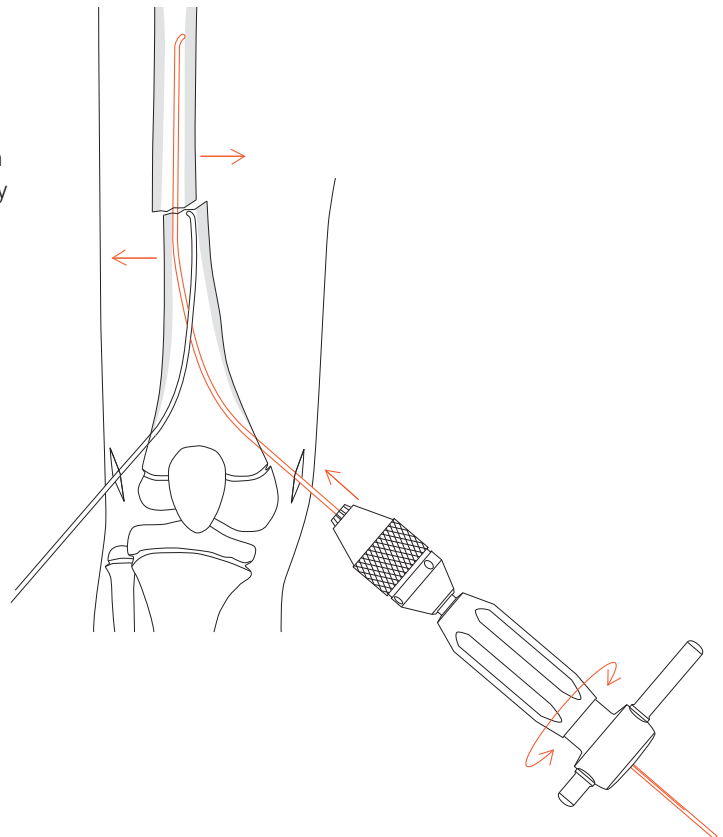


12

Advance nails

- If necessary, perform indirect fracture reduction either by turning the nails, pulling the leg or using the F-tool. Then advance the nails alternately across the fracture zone. Survey the passage of the nails with the image intensifier in both planes also on the other side of the fracture zone.

Note: Any nails that buckle as a result of the reduction manipulations must be replaced and discarded.



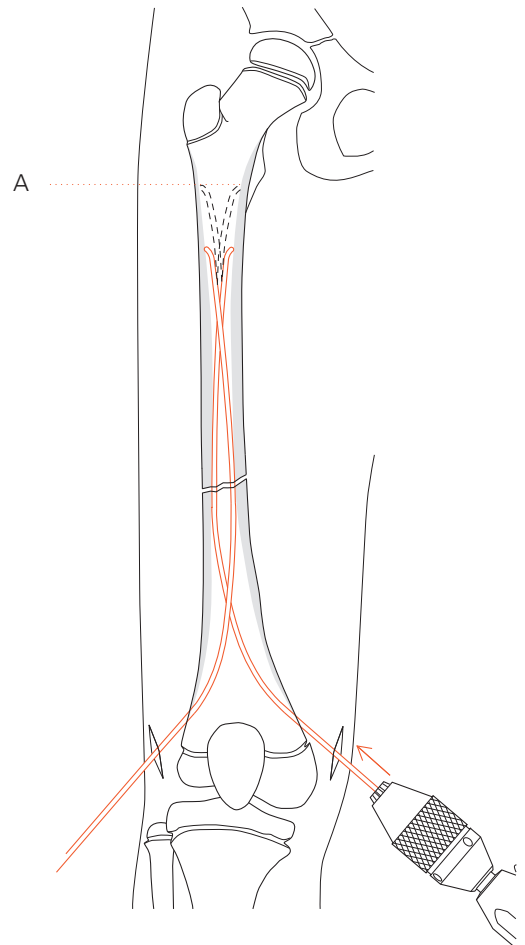
13

Check position of nail tips



Correctly align the nail tips in the proximal fragment in relation to the medullary cavity in the frontal plane. If the tips are correctly located, advance the nails in a proximal direction until the fracture is secured. The tips of the nails should only just reach the metaphysis (A). Ensure that the nails cross over for the second time only after they have passed the fracture zone.

Note: Do not, under any circumstances, turn the nail through more than 180° about its own axis or produce a “corkscrew effect” (more than two nail crossover points).



14

Check rotation



When the fracture is provisionally but firmly fixed, check rotation before final anchoring and, if necessary, align the nail tips correctly. If an extension table is used, aseptically release the leg from the extension so that the image intensifier can be used to check the axial alignment in the proximal femur.

15

Trim nails

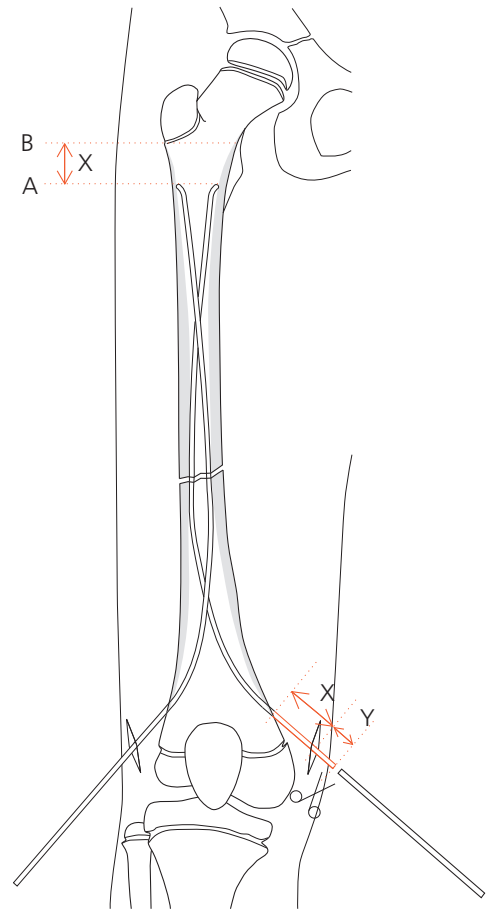
The nails must be trimmed to the desired length during the operation. The ideal cutting point is measured from the bone to the distal end of the nail.



Starting at the proximal end, estimate the distance (X) between the current position of the nail tips (A) and the definitive anchoring position (B) on the image intensifier projection. This distance plus an extraction length of approx. 1 cm (Y) produces the distance from the bone to the cutting point.

The nails can be trimmed using the Cutter for TEN (359.217). See page 11 for assembly and handling instructions.

Note: Excessively long nail ends result in pseudobursa formation and prevent free flexion of the knee. They can also perforate the skin and cause infections.



16

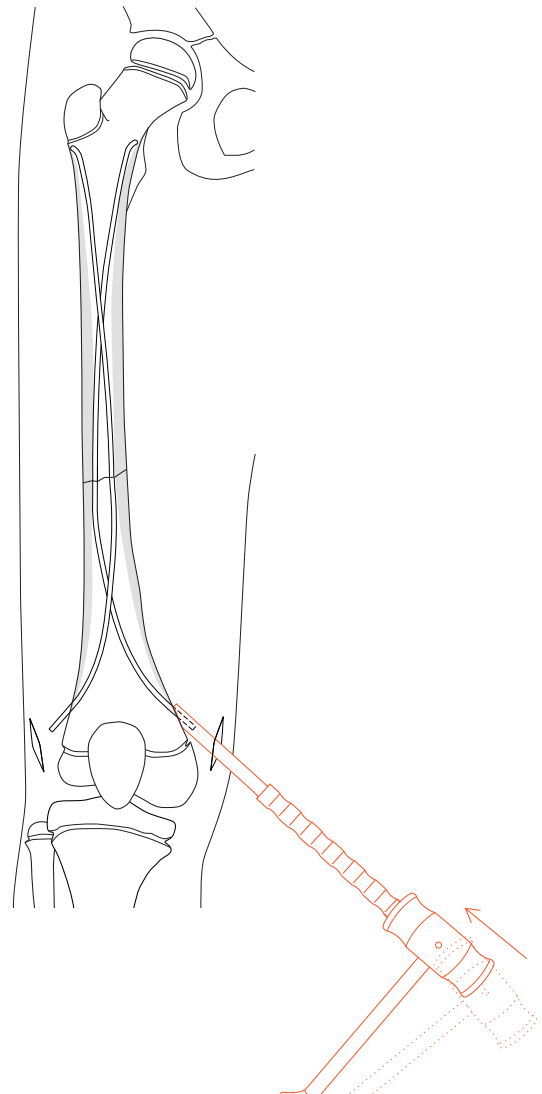
Final positioning and anchoring of nails

Advance the nails to the planned final position by applying gentle hammer taps to the bevelled Impactor (359.206). The bevelled part of the impactor must reach the cortical bone. This will ensure a projection of approx. 1 cm (Y) for subsequent removal.

Bend the nail ends upwards slightly with the bevelled impactor to facilitate subsequent implant removal.

Option

If deeper insertion of the nails is desired, apply careful taps with the straight Impactor (359.205).



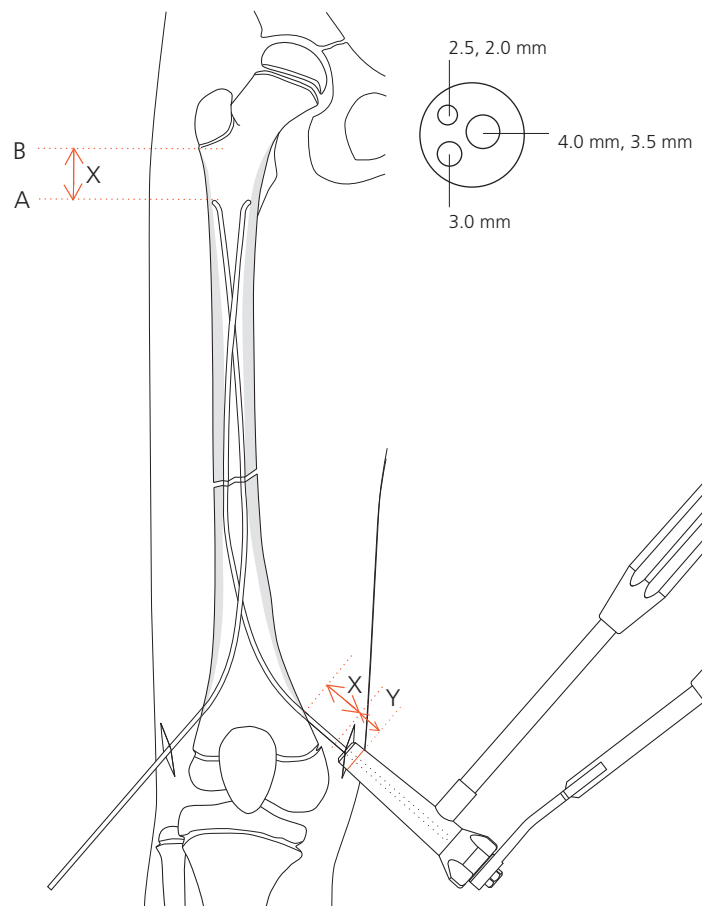
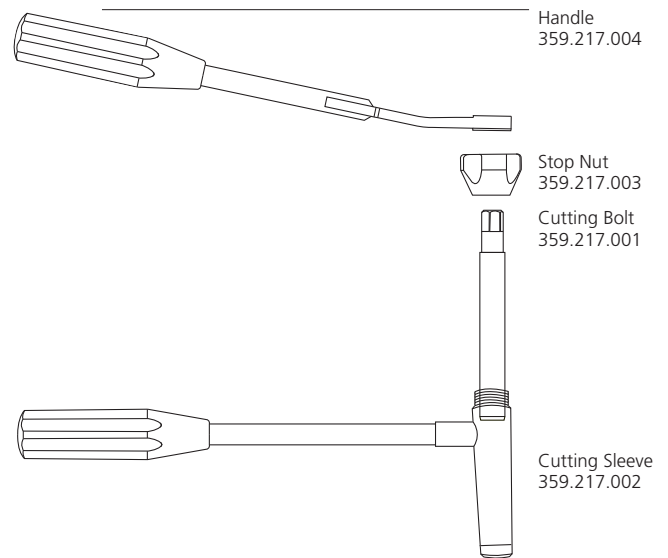
Assembly and handling instructions for the Cutter for TEN (359.217)

Loosen the stop nut on the cutter and turn the inner cutting bolt to the neutral position, i.e. engage the cutting bolt so that the lettering TOP is at the top. Retighten the stop nut.

Introduce the nail end to be cut through the appropriate opening of the cutting sleeve until the black marker ring on the outside of the sleeve reaches the desired cutting point on the nail. Locate the handle with ratchet over the cutting bolt and trim the nail.

After trimming, open the stop nut and remove the cut nail end.

If the cutting surface of the cutting bolt has become roughened, send the cutter to your Synthes representative for regrinding.



Additional applications

Femur – Descending technique	13
Radius and ulna	15
Radial neck	16
Humerus – Ascending technique	17
Humerus – Descending technique	18
Lower leg	19

Femur – Descending technique

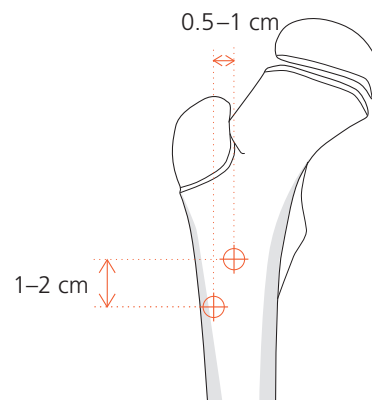
The descending monolateral technique is preferable for fractures of the distal third of the femur or the distal metaphysis. The fixation of metaphyseal fractures with the nailing technique does not correspond to the same biomechanical principles as the fixation of shaft fractures. However, a correct inner support for the stabilisation of the nail tips and therefore of the metaphyseal fragment must be guaranteed.

Note the following deviations from the standard technique (pp. 4–10):

Determine nail insertion points

For the descending technique, the monolateral insertion points are located antero-laterally in the subtrochanteric area. They are separated from each other vertically by approx. 1–2 cm and horizontally by 0.5–1 cm.

Note: The bone may split during nail insertion if the insertion points are placed too close to each other.

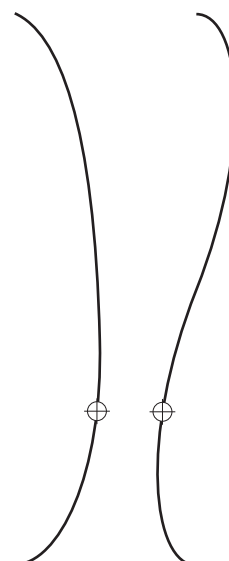

Perform incisions

The incisions should be 4–5 cm long so as to expose the femur through a short L-shaped cut in the M. vastus lateralis.

Pre-bend nails

To ensure correct internal bracing, i.e. with 3-point support, bend one of the nails into an S-shape so that the bracing occurs at the level of the fracture zone (⊕).

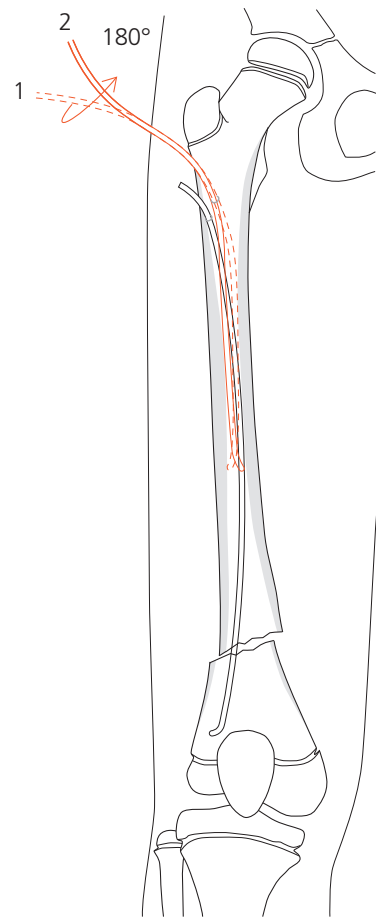


Insert first nail

- Introduce the simply pre-bent nail, reduce the fracture with the nail and achieve primary stabilisation.

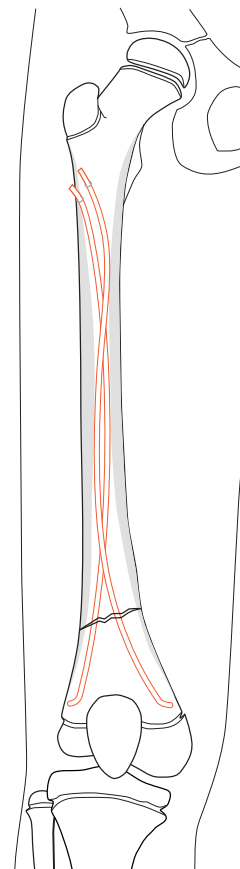
Insert second nail

- Insert the S-shaped pre-bent nail (1). After the first contact with the cortical bone on the opposite side, turn the nail through 180° (2).



Final positioning and anchoring of nails

- Advance the nails to the epiphyseal plate and align the nail tips so that they diverge from each other.



Radius and ulna

In the forearm the two bones are nailed in a counter-rotating manner using just one nail for each bone, since the radius and ulna form a single unit together with the interosseous membrane.

Note the following deviations from the standard technique for the femur (pp. 4–10):

Determine nail diameter

The nail diameter should be about two thirds of the medullary isthmus.

Determine nail insertion points/Perform incisions

Radius: Splint the radius with the ascending technique. The insertion point is approx. 2 cm proximal to the distal epiphyseal plate. From this point make a 2–3 cm incision on the radial side proceeding distally. Expose the superficial branch of the radial nerve and retract to one side.

Ulna: Splint the ulna with the descending technique. The insertion point is about 2 cm distal to the apophyseal plate. Make the incision on the dorsoradial side, sparing the olecranon apophysis.

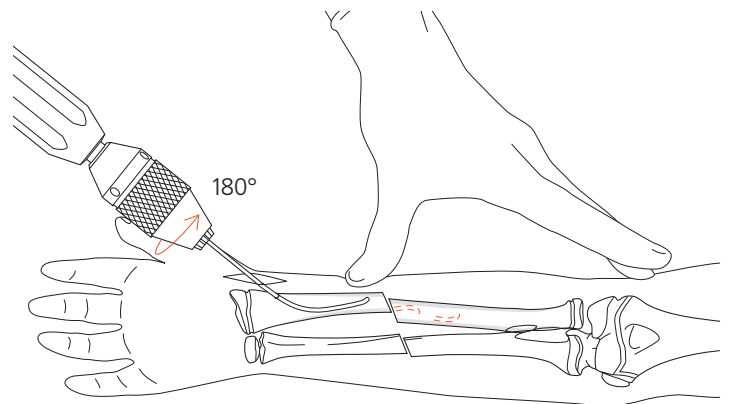
Insert nails

Advance the nails from the distal radius and the proximal ulna up to the fracture site.



Ideally, the bone that is most difficult to reduce (usually the radius) should be splinted first since this allows better fracture reduction.

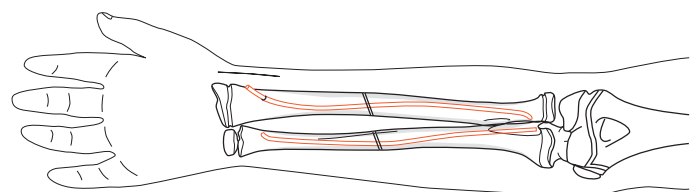
Note: If neither the radius nor the ulna can be reduced after several attempts, a muscle interposition is the most likely cause. In such cases, the fracture can be reduced openly through a small incision over the fracture site of one of the bones.



Final positioning and anchoring of nails

Align the nails so that the tips point toward each other, thereby providing oval bracing of the interosseous membrane. The bones take up their normal curved position.

To avoid skin irritation, the nail ends should not project from the bone by more than 5–6 mm.



Radial neck

Because of its flexibility, the TEN is very suitable for the closed reduction and fixation of neck and head fractures of the radius. Do not pre-bend the nails for these indications.

Note the following deviations from the standard technique for the femur (pp. 4–10):

Determine nail diameter

Select a \varnothing 2.0 or 2.5 mm nail for reducing a fractured neck of radius.

Insert nail

Insert the nail as for a normal radius fracture.

Advance nail to the fracture zone

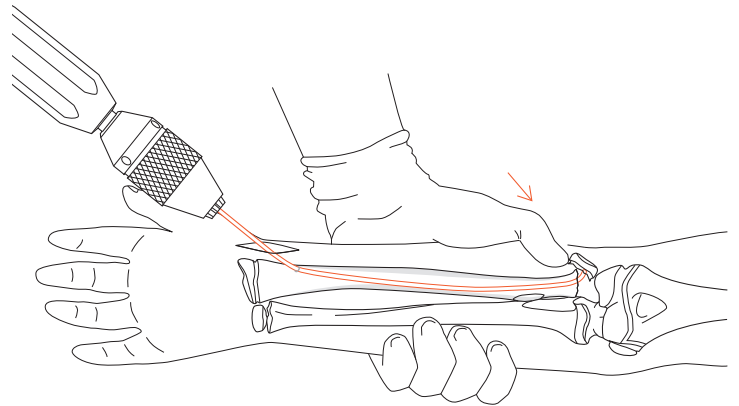


Advance the nail up to the fracture with gentle hammer taps and rotating movements. In the event of severe dislocation, apply external pressure to the head of the radius to place it in front of the nail tip.

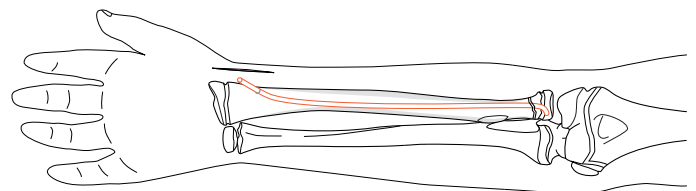
A severely dislocated head of radius can be moved toward the nail and reduced with the aid of a \varnothing 1.2 or 1.6 mm Kirschner wire (joystick method).

Final positioning and anchoring of nail

Decompact the fracture by applying slight axial pressure to the nail. Reduce the fracture definitively by rotating the nail through 180°.



Final position



Humerus – Ascending technique

The ascending, monolateral nail technique is used for fractures of the proximal humerus and the humeral shaft, while the descending monolateral technique is used for fractures of the distal humerus.

Note the following deviations from the standard technique for the femur (pp. 4–10):

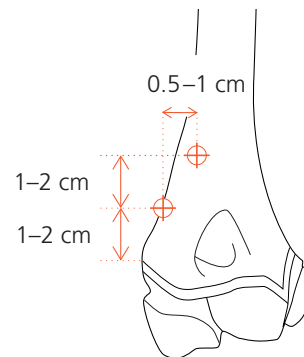
Ascending technique

Perform ascending nailing of the humerus as for the descending nailing of the femur.

Determine nail insertion points

Choose a radial approach for the ascending technique. An ulnar approach risks damaging the ulnar nerve and must be avoided.

The distal insertion point is located 1–2 cm above the epiphyseal plate. The second insertion point is located about 1–2 cm proximal to the first and is displaced medially by 0.5–1 cm.



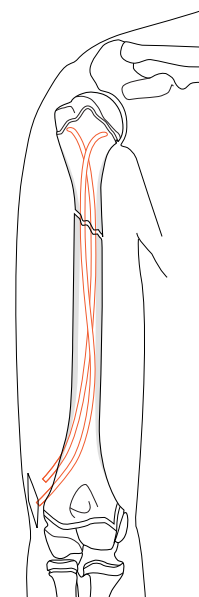
Perform incision

Make a 4–5 cm lateral incision above the radial epicondyle. Expose the radial edge of the humerus on the ventral side of the intermuscular septum.

Open medullary cavity

Ideally, a drill should be used to open up the very hard cortical bone.

Final position



Humerus – Descending technique

Descending technique

Perform descending nailing of the humerus as for the ascending technique.

Note the following deviations from the ascending technique for the humerus (p. 17):

Determine nail insertion points

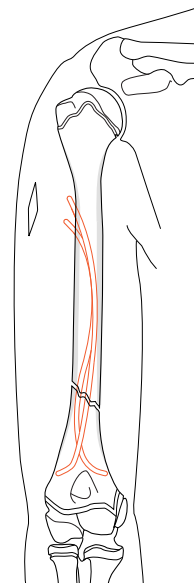
For the descending technique, the insertion points are located on the lateral humerus level with the attachment point of the deltoid muscle. The nail insertion points are separated from each other vertically by 1.5–2.5 cm and horizontally by 0.5–1 cm.

Perform incision



Make a 4–5 cm skin incision and expose the subperiosteal humerus distal to the insertion point.

Final position



Lower leg

Indications

Lower leg and isolated tibial fractures should preferably be treated conservatively.

Lower leg fractures constitute a special indication for internal fixation by TEN. Nailing is indicated in:

- closed, unstable lower leg fractures from the age of 9
- irreducible and non-retainable fractures
- polytrauma and severe craniocerebral trauma

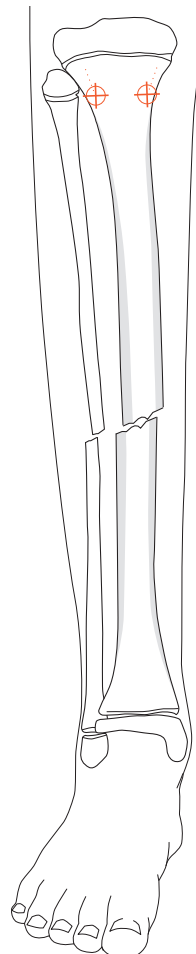
Since the tibia is positioned off-centre in relation to the surrounding muscles and since it possesses a triangular cross-section, particular care is indicated when placing the nails.

Always nail the tibia using the descending technique. Do not use the ascending technique for the tibia.

Note the following deviations from the standard technique for the femur (pp. 4–10):

Determine nail insertion points

The nail insertion points are located on the medial and lateral sides of the tibial tuberosity.



Perform incisions

Make a 2–3 cm skin incision from each planned insertion point in the cranial direction.

Note: Do not damage the proximal tibial epiphyseal plate and tibial apophysis during perforation of the cortical bone.

Check position of nail tips

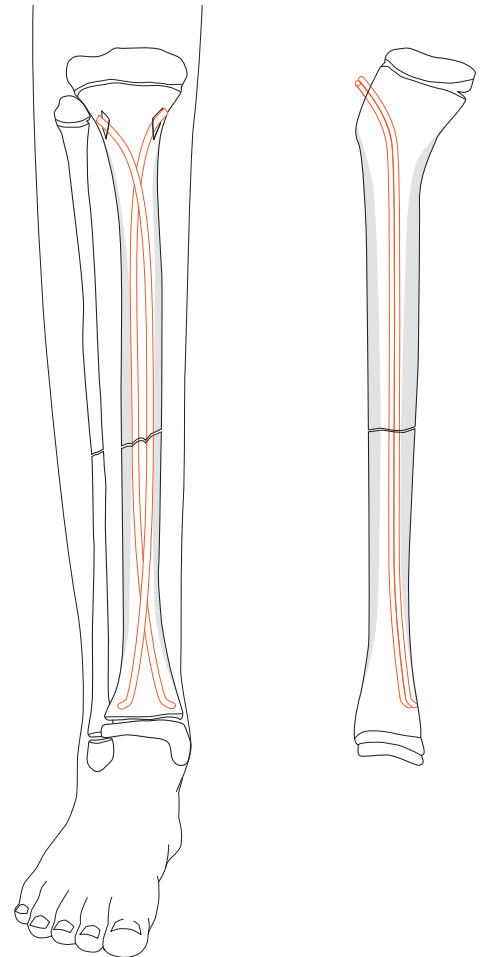
Because of the triangular shape of the tibial medullary canal, both nails tend to lie dorsally, which would result in recurvation.

Before hammering the nails home, turn the tips of both nails slightly posteriorly so as to achieve the physiological antecurvation of the tibia.

Note: Compress the fracture to prevent fixation in distraction.

Trim nails

In view of the minimal soft tissue cover, keep the nail ends short and do not bend upward.

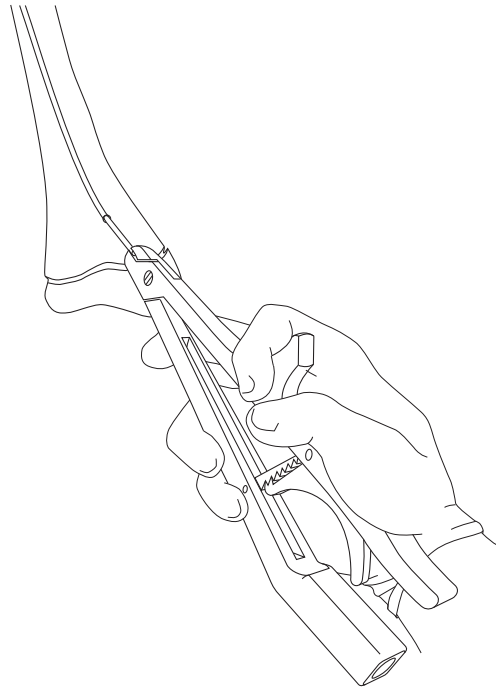


Implant removal

Remove implants

The following description for removing the TEN is independent of the indication.

Enter through the old incision site and expose the nail end. Using the Extraction Pliers (359.215) grasp the nail, bend upward slightly and withdraw. If the nail end is tight up against the bone, the bevelled Impactor (359.206) can be used to help bend the end upward.



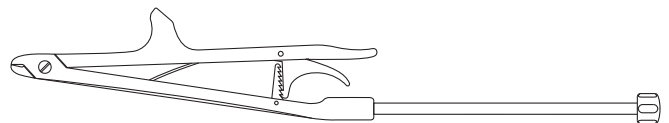
Option

If necessary, screw the Hammer Guide (359.218) tightly into the connecting thread of the extraction pliers using the \varnothing 4.5 mm Pin Wrench (321.170) and knock the nail out by firm blows along the hammer guide with the Combined Hammer (359.221).

Repeat the procedure for the second nail.

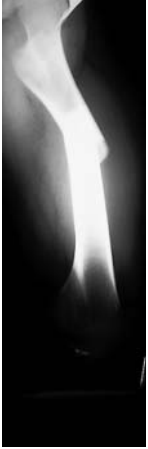Alternative

Remove the nails using the flat-nosed Pliers (359.204) and the combined hammer or the 500 g Hammer (399.420).

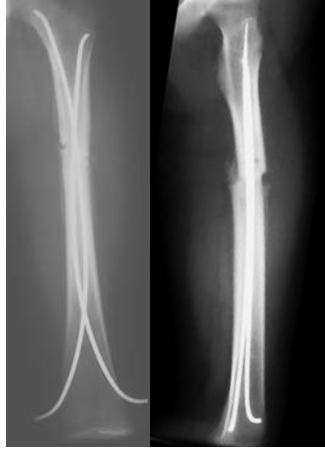

Case studies

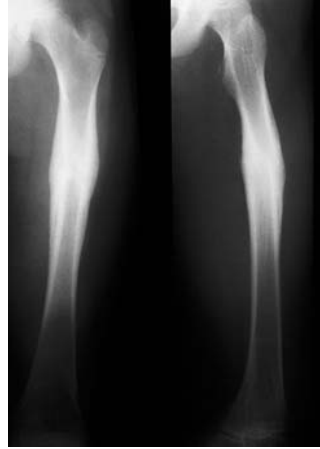Femur – Standard technique (pp. 4–10)



Preoperative

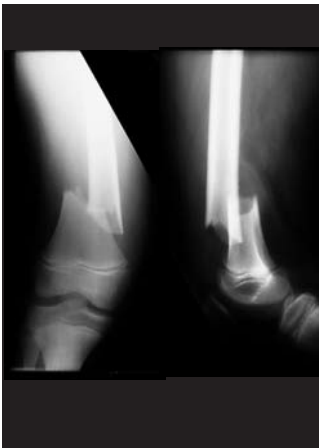

Postoperative

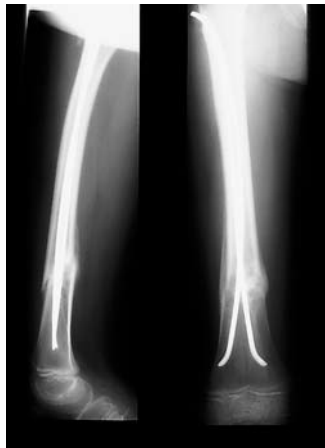

Union

Femur – Descending technique (pp. 13/14)

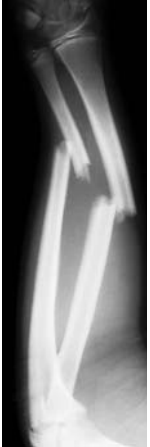

Preoperative

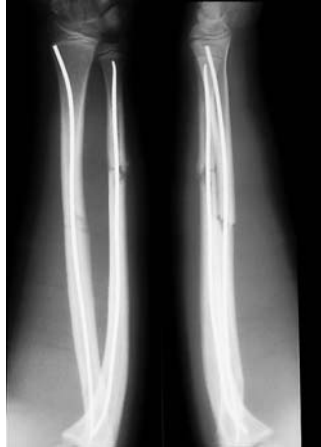

Postoperative

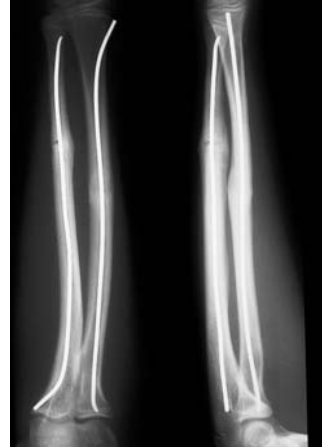Radius and ulna (p. 15)



Preoperative

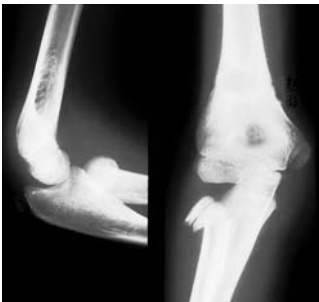

Postoperative

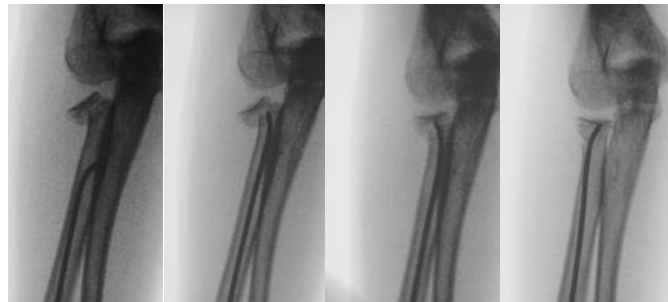

Union

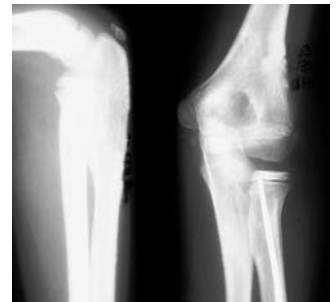
Radial neck (p. 16)



Preoperative

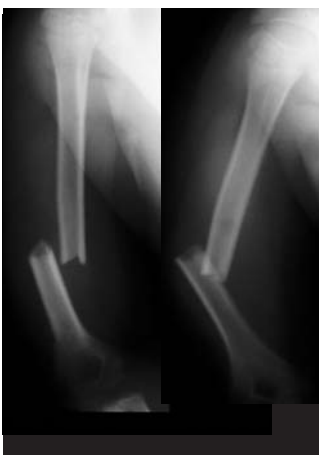

Reduction

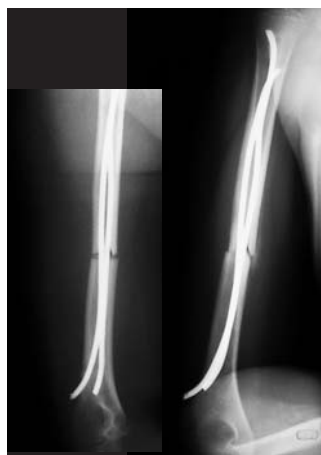

Union

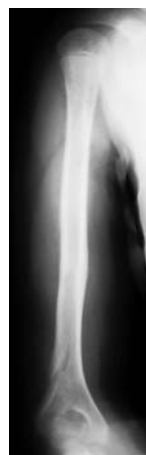Humerus – Ascending technique (p. 17)



Preoperative

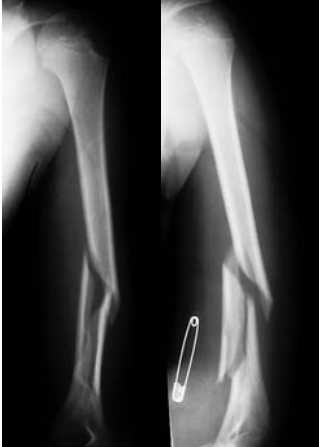

Postoperative

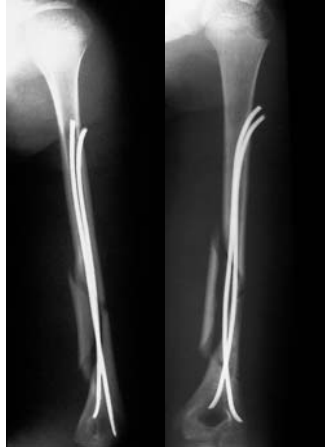

Union

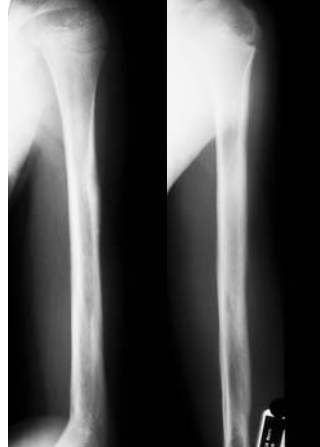Humerus – Descending technique (p. 18)



Preoperative

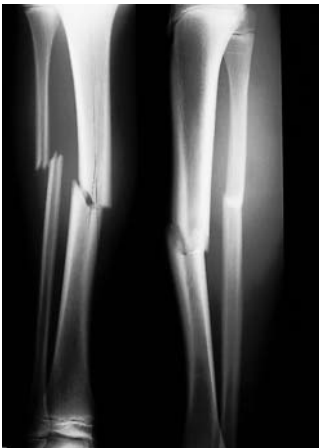

Postoperative

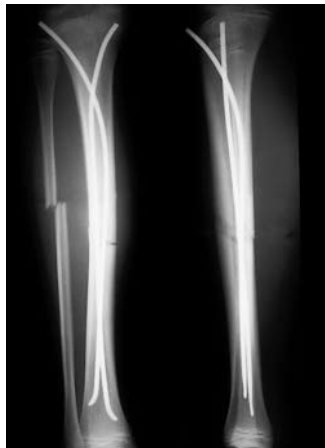

Union

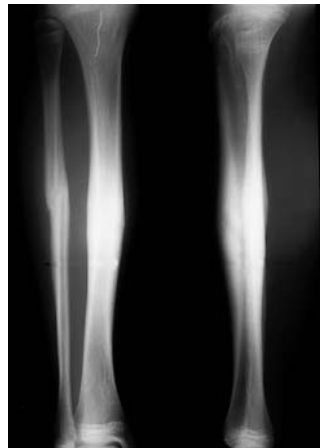Lower leg (p. 19/20)



Preoperative



Postoperative



Union

Scientific consultant and X-ray material by
Dr. T. Slongo, Inselspital/Berne, Switzerland

Bibliography

Dietz HG et al (1997) Intramedulläre Osteosynthese im Wachstumsalter. Urban & Schwarzenberg, München

Ligier JN, Métaizeau JP, Prévot J, Lascombes P (1988) Elastic stable intramedullary nailing of femoral shaft fractures in children. J Bone Joint Surg; 70-B: 74-7

Métaizeau JP (1988) Ostéosynthèse chez l'enfant par E.C.M.E.S. Sauramps Médical, Montpellier

Rehli V, Slongo T (1991) Die elastisch-stabile endomeduläre Schienung (EES) nach Prévot – Eine ideale Methode zur Versorgung kindlicher Schaftfrakturen. Z Unfallchir Versicherungsmed 84: 177-81

Texhammar R, Colton C (1994) AO-Instrumente und -Implantate. Springer, Berlin



Synthes GmbH
Eimattstrasse 3, CH-4436 Oberdorf
www.synthes.com

Presented by:



CE
0123